

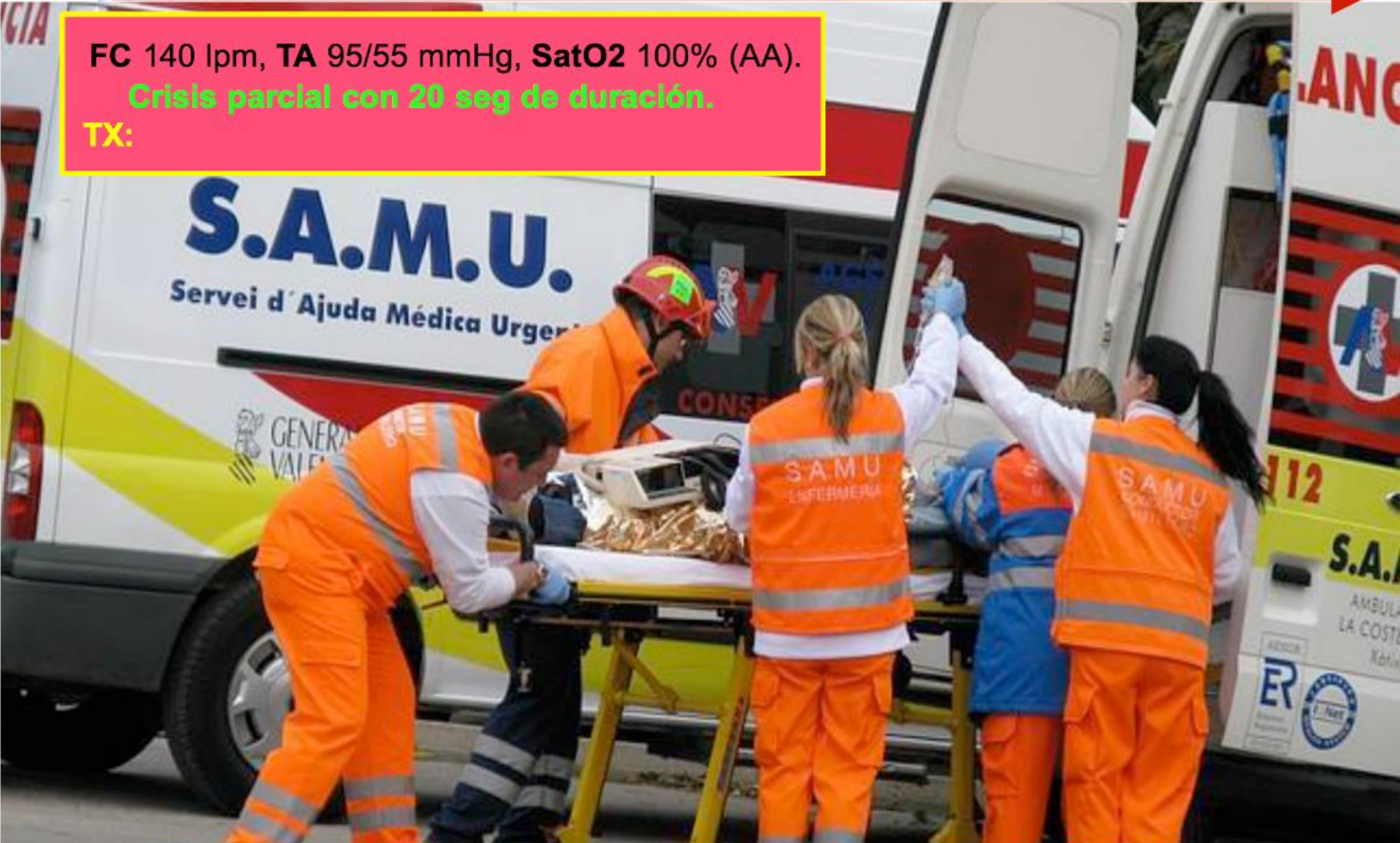ELCHE
17-18/10/16

18/10/16:11:00

U.C.I.P.



FC 140 lpm, TA 95/55 mmHg, SatO2 100% (AA).
Crisis parcial con 20 seg de duración.
TX:



ELCHE
17-18/10/16

18/10/16:11:00

U.C.I.P.

30:00 min.



Lactante 49 días
Peso: 4.5 kilos.
TA 140/50 mmHg.
FC 140 lpm.
SatO2 100% (AA).
T° 37°C.
PIM II: 95,89%.

Nueva crisis.
TX: levetiracetam.
(120 mg – 45 mg c/12 hrs).

TRATAMIENTO

- Levetirzcetam IV.
- Rivotril IV de rescate.

A photograph showing a variety of pharmaceuticals including white, red, blue, yellow, and green pills and capsules scattered on a light-colored surface.

AS: HB 7,4 g/dl. → **TRANSFUSIÓN.**

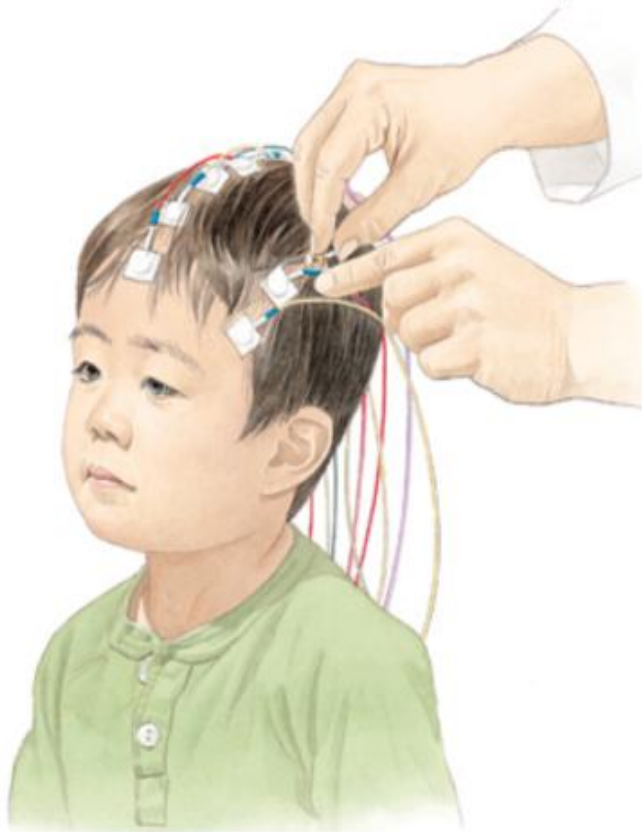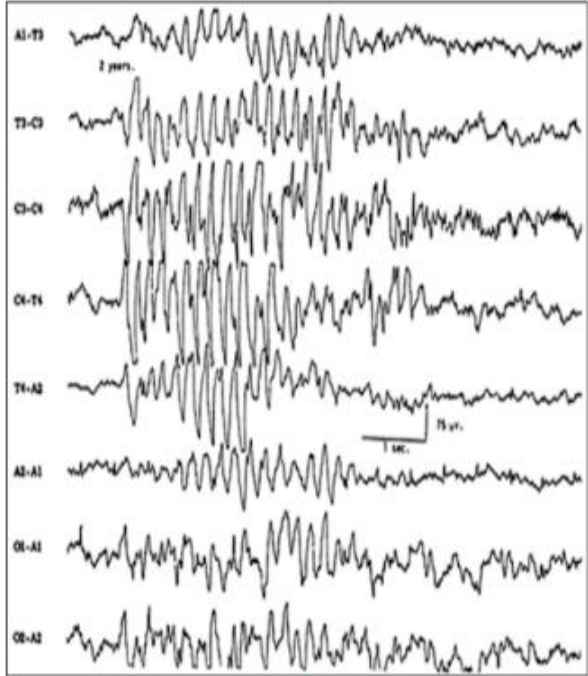
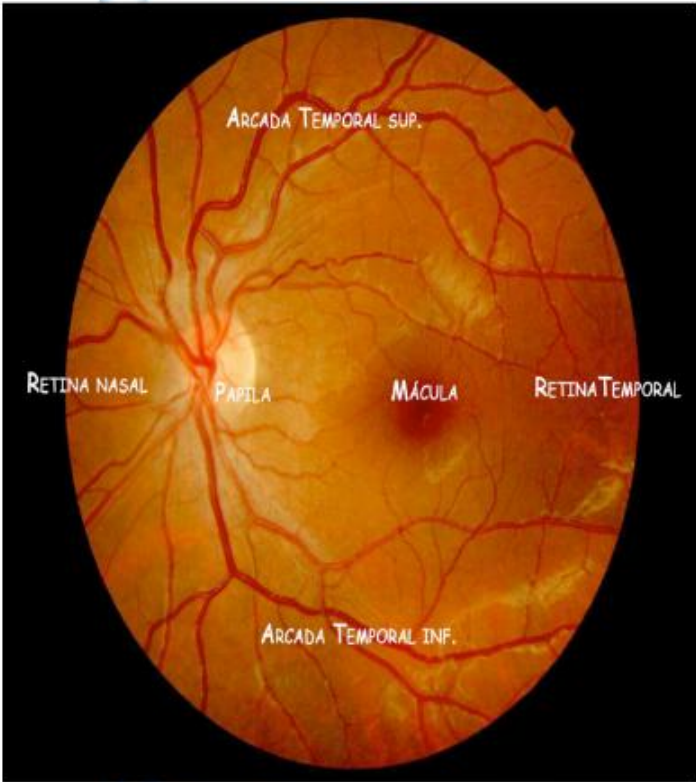
G.V: PH 7,31- PCO2 34- HCO3 17.1 – Lac 2.1 – EB -9.

RX TORAX:

ELCHE
17-18/10/16

U.C.I.P.

1º dia.



EEG ANORMAL. Actividad cerebral deficientemente estructurada y moderadamente lentificada para su edad. Episodio **comicial parcial** hemisférico izq. secundariamente generalizado de 2 min de duración.

ELCHE
17-18/10/16

U.C.I.P.


19/10/16



crisis comiciales

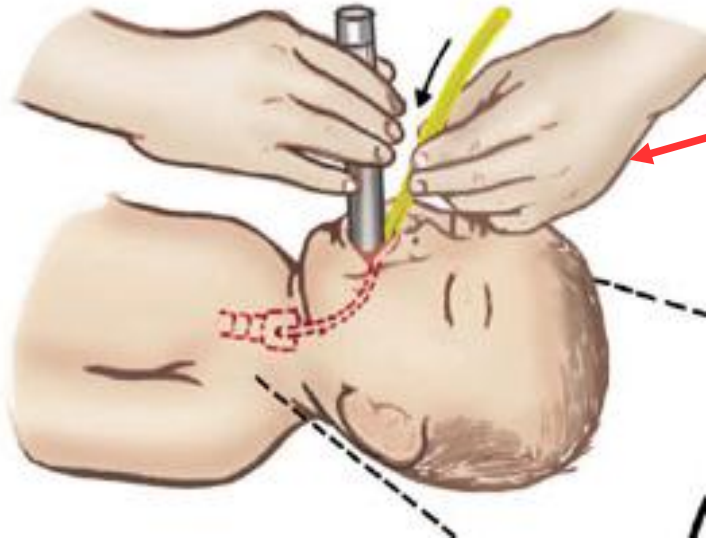


estatus epiléptico

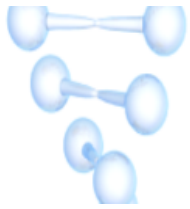


ACIDOSIS
metabólica.

Hipotensión.



Resucitación con fluidos.
Apoyo vasoactivo.
Bicarbonato.



GASOMETRIA VENOSA

	18/10/16	19/10/16		19/10/16	20/10/16	20/10/16	20/10/16	20/10/16
HORA	13:07 Hrs.	PRE - IOT	POST - IOT	22:48 Hrs.	01:25 Hrs.	02:13 Hrs.	02:36 Hrs.	02:56 Hrs.
PH	7,31	7,31	7,55	7,38	6,84	< 6,8	7,09	7,08
pCO2	34	48	22	30	65	76	73	77
HCO3	17.1	24	19,7	17,9	12	Incalc.	22,5	23,2
LAC	2.1	0,8	1,6	2,4	10,6	19,3	18,7	16,5
EB	-9	-2,6	-2,8	-7,4	-21,5	Incalc.	-7,5	-6,9
AG	10	7	8	10	20	Incalc.	30	25

ELCHE
17-18/10/16

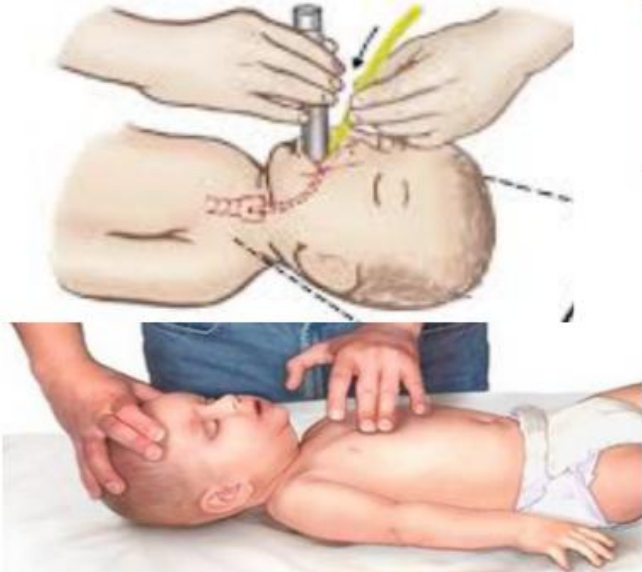U.C.I.P.

19/10/16

20/10/16



**ACIDOSIS METABÓLICA
LACTACIDEMICA.**



Bradicardia.

Atropina.

P.C.R.

R.C.P.

F.V.

Desfibrila 15 J.

Bradicardia.

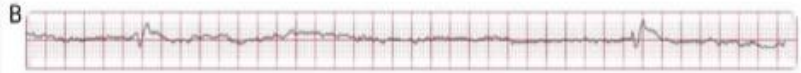
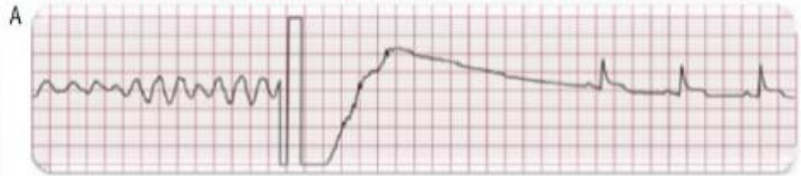
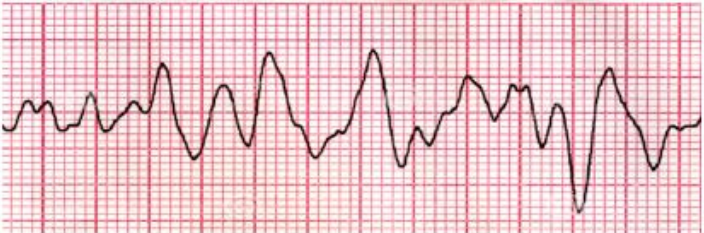Atropina.

P.C.R.

R.C.P.

**EXITUS
04:15**

1 hr y 40 min - 20 adren.



A large, multi-story, light-colored building with a curved facade. The building has many windows and a prominent entrance area. In the foreground, there are several trees, a road with a crosswalk, and a row of white cars parked. The sky is blue with some clouds.

HOSPITAL GENERAL UNIVERSITARIO